

2018 Singapore Echo
Chai Siang Chew, Changi General Hospital

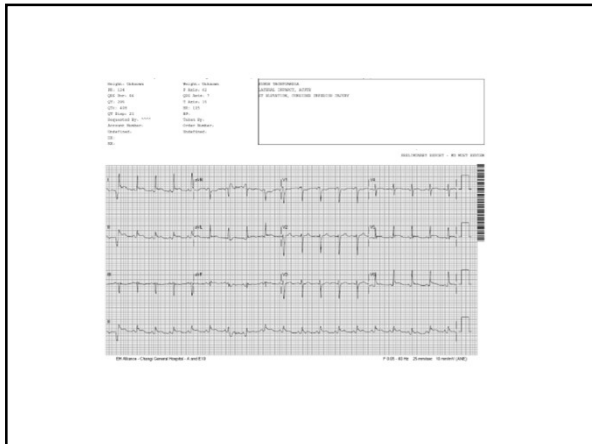
Cryptic Conundrum

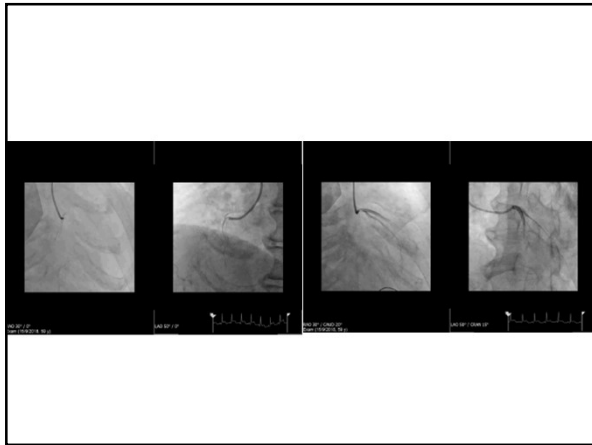
Case 1

- 59 Male Chinese
- Fever on and off for 1 week
- On and off chest pain associated with dyspnea
- 6:45 am had chest pain again while taking his usual morning walk

What would you like to do?

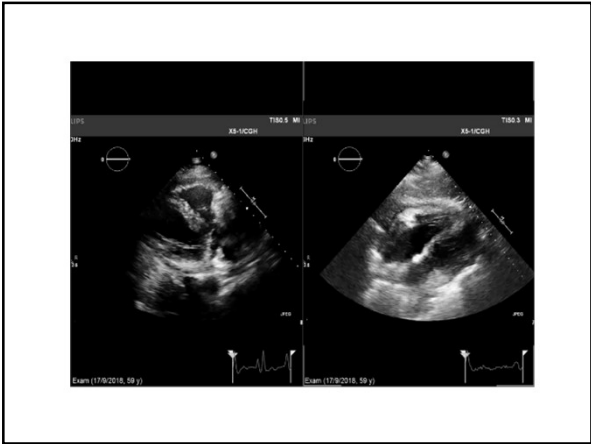
- 1. ECHO
- 2. CT Thorax
- 3. CXR
- 4. ECG

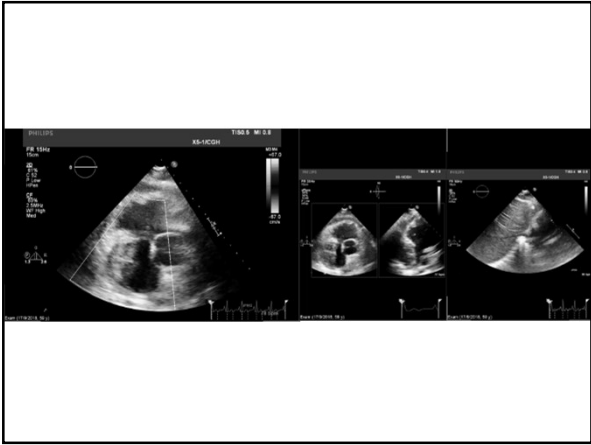


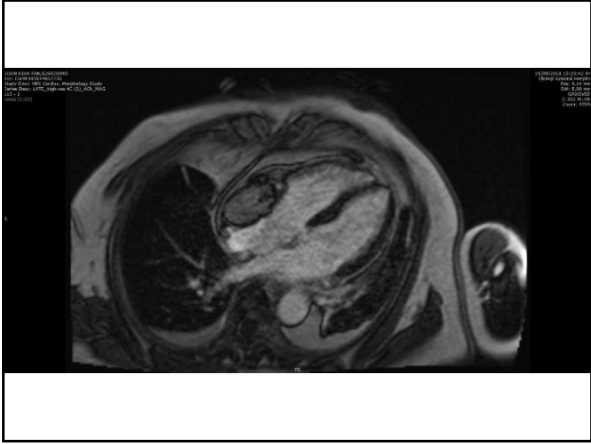


What would you like to do next ?

1. CT Thorax
2. CXR
3. Echo
4. Cardiac MRI





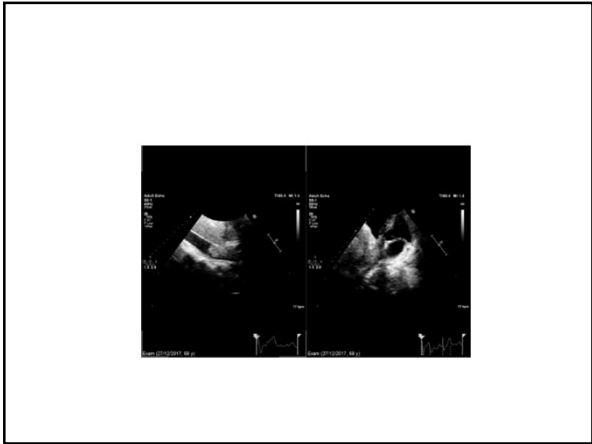


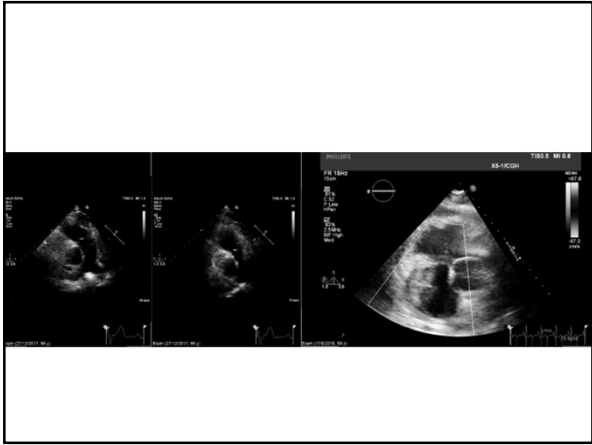
- Pending PET CT , Cardiac mass biopsy .
- Possible sarcoma versus lymphoma (FBC normal)

Case 2

- 68 Male Chinese
- Background : Hypertension, hyperlipidemia, Ischemic heart disease s/p PCI at Mount E
- Presented with cough associated with exertional dyspnea and reduced effort tolerance. He had abdominal and bilateral lower limb swelling as well

- Would you want to order an Echo for this case ?





• How would you investigate this patient further?

