

Echo Conundrums

- the case of the flap that didn't.....

- a Dragnet special

CONNUNDRUM:

- a problem that is difficult to deal with – a problem that needs solving

- a question that is a trick, often involving a humorous use of words that have two meanings

DRAGNET

- a systematic search for someone or something, especially criminals or criminal activity.



WARNING :

The story you are about to hear is true. The names have been changed to protect the innocent

AND
THE IGNORANT

*As narrated by Dr Friday-
(not my real name)*

Here are the facts- *Just the facts*

- It was a warm dreary afternoon clinic in June 2002
- Mr A (not his real name) was seen in the cardiac clinic by a newly minted Consultant Cardiologist Dr B (not his real name)

Mr A's problem:

- History of congenital heart disease – a large VSD– mainly with left to right shunting
- He was on routine f/u with his regular cardiologist Dr C (not her real name) – a seasoned veteran who had seen him regularly for many years

Here are the facts- *Just the facts*

- So far Mr A (not his real name) was well and clinically asymptomatic in all his f/u visits with Dr C
- Mr A had regular echos done by Dr C over the years which were largely unchanged

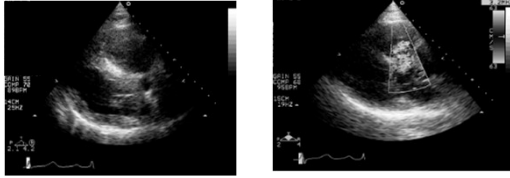
Here are the facts- *Just the facts*

BUT THIS TIME THINGS WERE DIFFERENT.....

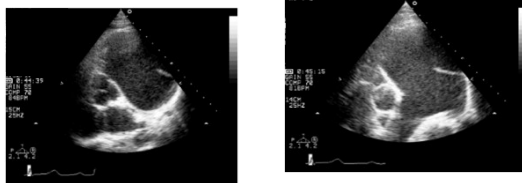
- Dr C left for private practice.....leaving Dr B to take over
- In his zealous pursuit of thoroughness albeit inexperience, Dr B ordered a repeat echo for Mr A on his visit to his clinic on that dreary June afternoon.....

The events that transpired following that fateful visit are shown for your assessment and judgement

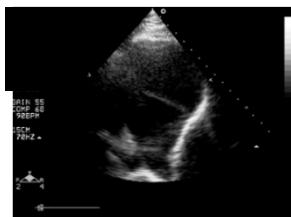
THE FATEFUL
ECHOCADIOGRAM.....



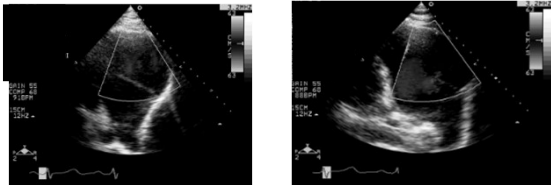
THE ECHOCADIOGRAM-THE PLOT
THICKENS....



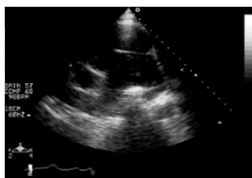
THE ECHOCADIOGRAM-THE PLOT
THICKENS....



THE ECHOCADIOGRAM-MORE IS REVEALED



THE ECHOCADIOGRAM-MORE IS REVEALED



THE SUBSEQUENT EVENTS

PANDEMONIUM BREAKS OUT.....

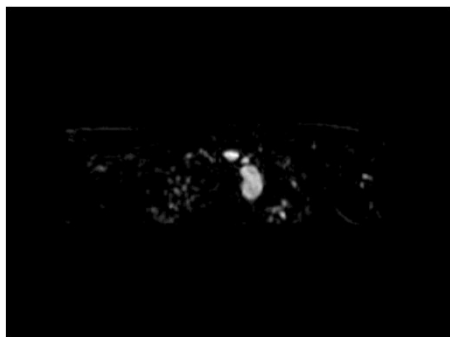
- A provisional diagnosis of Pulmonary artery dissection is made...
- Mr A is sent rapidly from the clinic by ambulance to the CCU
- He had lines inserted
- An urgent cardiothoracic consult was arranged with a view to urgent/ emergent surgery
- Family was called in to have a possible last goodbye- (a priest was there too - but this can neither be confirmed nor denied....)

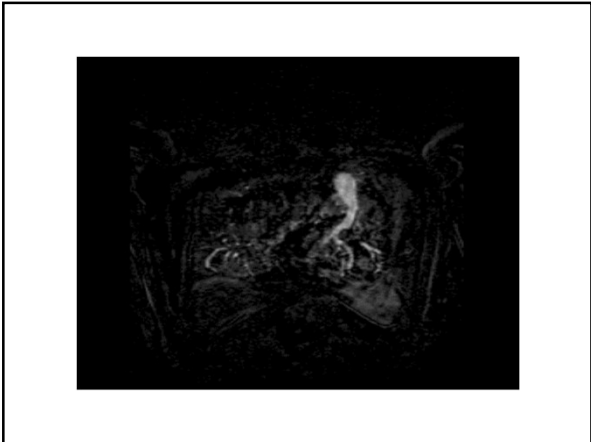
UNFOLDING EVENTS

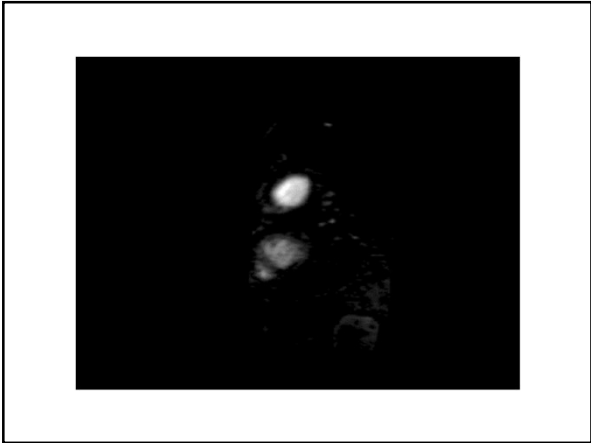
Common sense prevails.....

- The urgent consult was called off
- A department wide meeting was held the next day
- Meanwhile A hastily arranged MRI was arranged to assist in the case err...diagnosis

MORE EVIDENCE IS PRODUCED....THE MRI







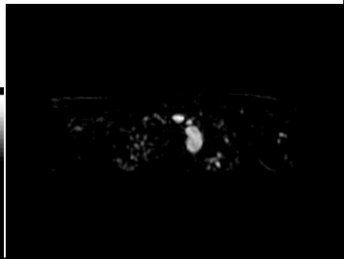
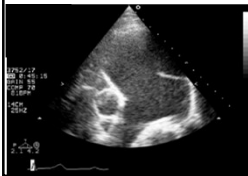
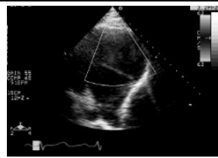
EPILOGUE

- AN UNEXPECTED TURN OF EVENTS.....
- The expert CTS sitting in the audience gave a loud guffaw and uncontrollable laughter erupted- (*facts not fully corroborated*)

QUESTION

- WHAT DO YOU THINK IS THE DIAGNOSIS...?
- a) Pulmonary Dissection
- b) Artifact
- c) Iatrogenic object –eg catheter of sorts
- d) This is a fictional story- fake news- it never happened...
- e) OR was it something else.....

Here are the Clues



Thank You

*The events you have just witnessed were true
Any semblance of similarity to persons or persons
unknown is purely coincidental and has no bearing to
the outcome of this case*